

The eye in cystinosis

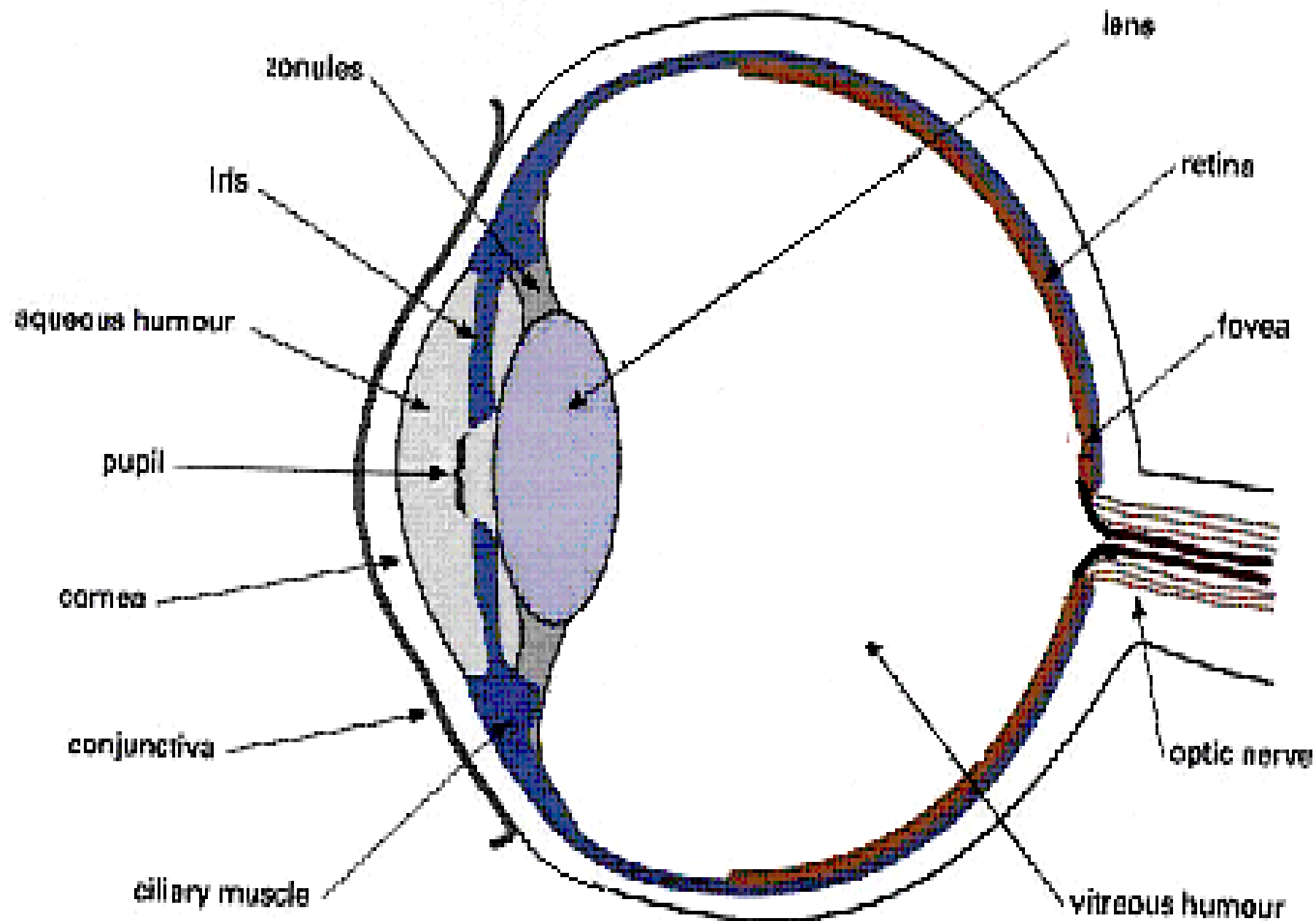
Elizabeth Graham
Medical Eye Unit
St Thomas' Hospital
London SE1 7EH

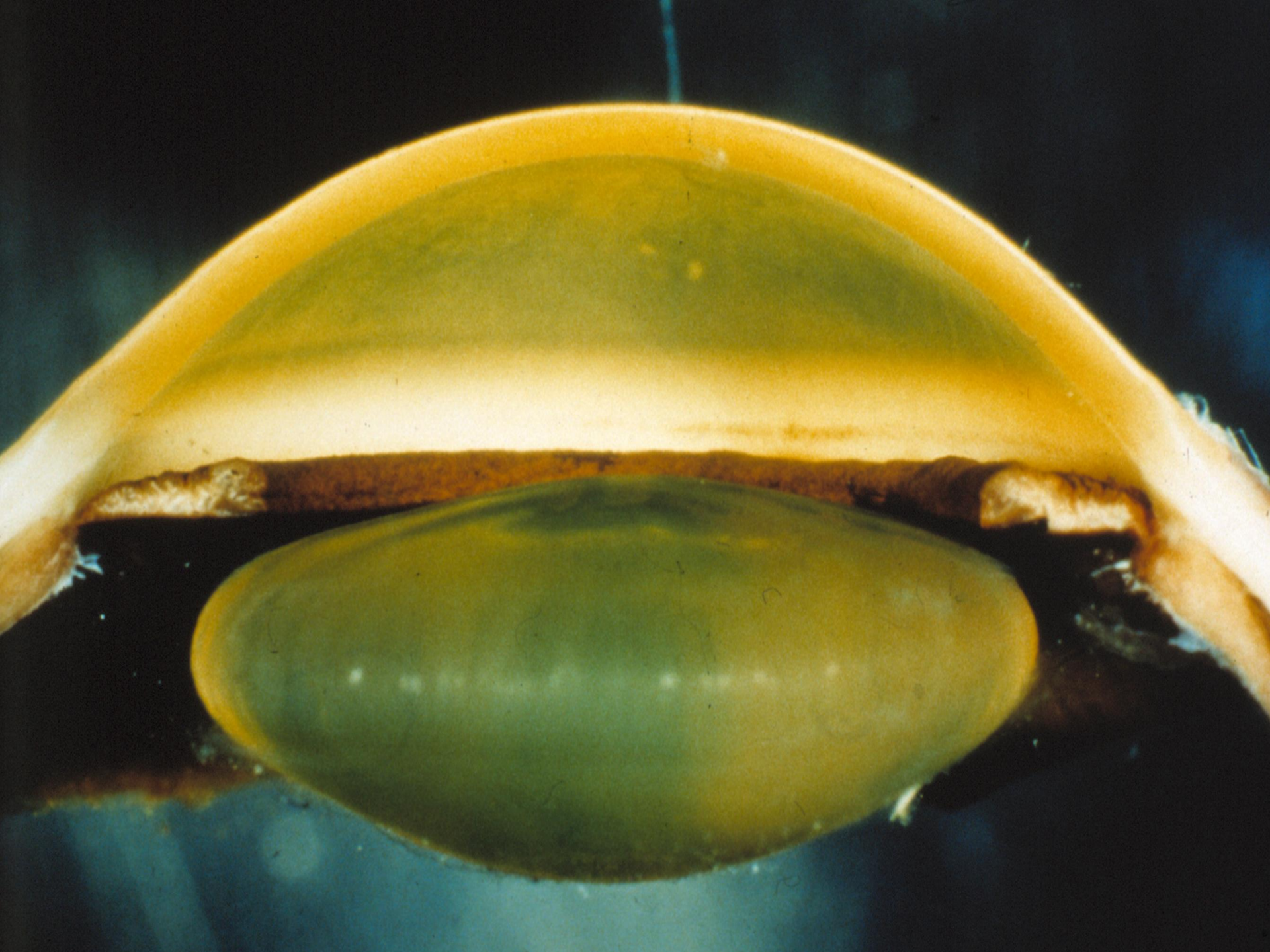The eye

- The fourth most common system affected by genetic disease
- Age of onset of ocular abnormalities in metabolic disease is variable – birth to early adult hood
- Exact mechanisms of how ocular defects occur is unknown – direct toxic effect, accumulation of normal metabolites, deficient energy metabolism
- Generally symmetrical bilateral involvement

Cystinosis

- Rare autosomal inherited disorder
- Cystine accumulates within cellular lysosomes because of defect in its transport across lysosomal membrane due to mutation in CTNS gene
- Free non protein cystine accumulates in concentrations 50 – 100 times normal, forming crystals
- Cysteamine hydrochloride is a free thiol with marked cystine depleting ability







Infantile onset cystinosis – a lysosomal disorder – a text book view in 1990's

- Photophobia
- Sneezing in bright light
- Recurrent erosions, reduced corneal sensation
- Corneal crystals from 2 months
- Needle shaped, polychromatic
- Crystals may involve iris and conjunctiva
- Retinal degeneration – late
- ? Glaucoma in 2nd decade
- 33% lose driving vision , 14% legally blind

Ocular Pathology of Cystinosis

with particular reference to the **elusiveness** of the corneal crystals

- 9 y.o. patient died of ‘uraemic pneumonitis’
- Tinsel like opacities in cornea easily observed on slit lamp, but not present on microscopy
- ? Dissolved in aqueous solvent
 - David G Cogan and Tochiro Kuwbara (Boston
 - A.M.A Archives of Ophthalmology 1960 63 75-81

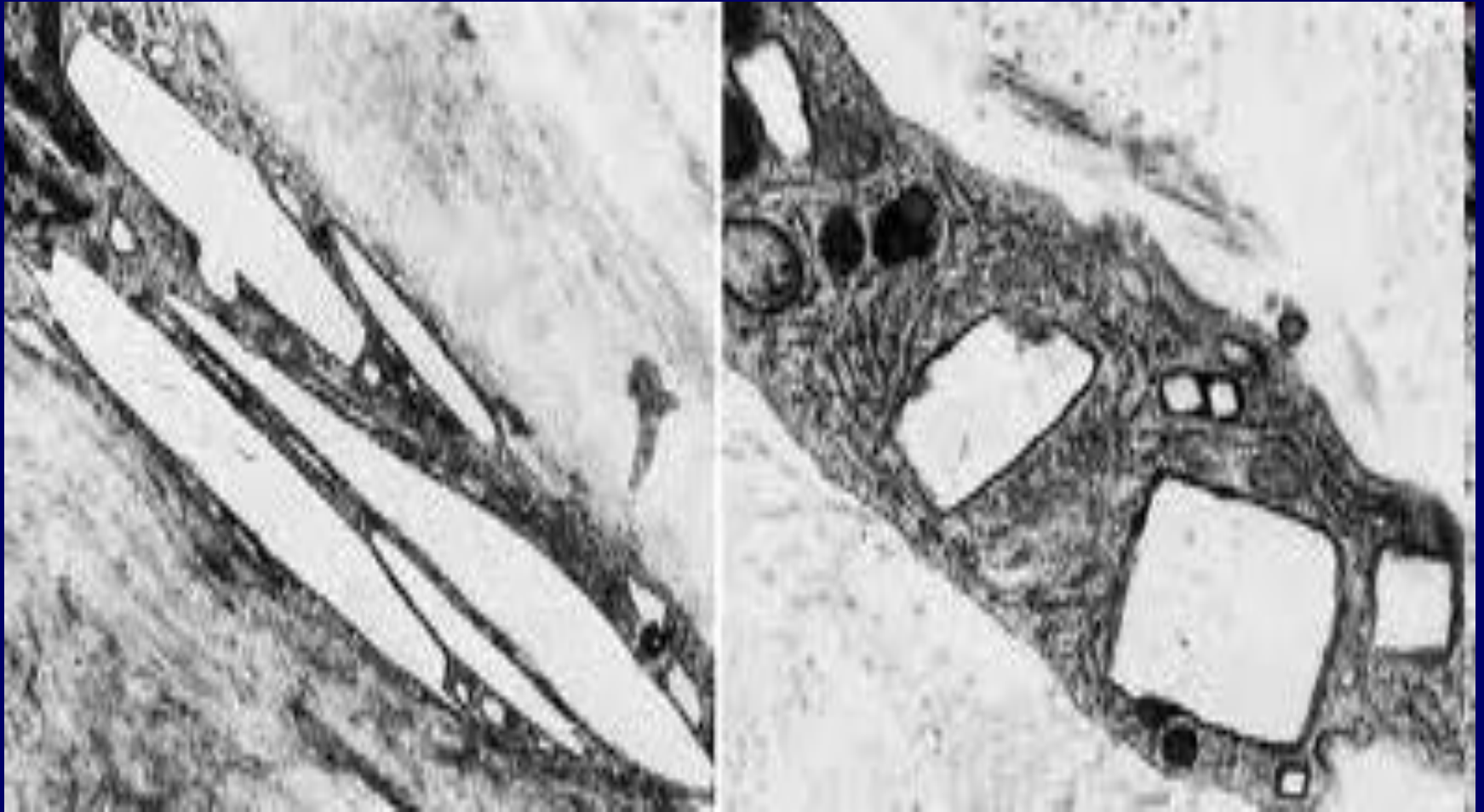
Ocular pathology of cystinosis 2

- Crystals in cornea are **morphologically distinctive**
- Uniform **needle** shaped structures
- Best seen in thick, flat or macerated sections with dark field illumination or crossed polaroids
- Less evident in 'better preparation' sections
- Chromatography confirmed crystals are cystine not tyrosine

Ocular pathology of cystinosis 3

- Elsewhere in eye crystals similar to those elsewhere in the body
- Various shapes including 'rodlets' but not needle shaped
- Abundant in conjunctiva, ciliary processes and stroma, choroid
- Less abundant in ciliary muscle, iris and sclera
- Very rare in retina and optic nerve

Cystine crystals

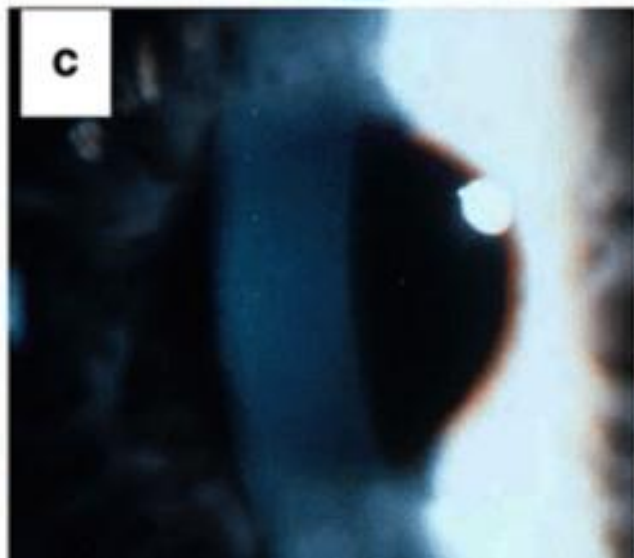
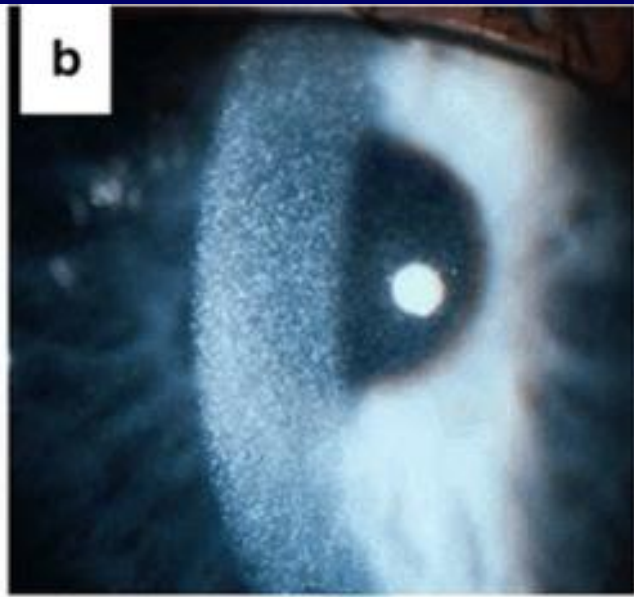
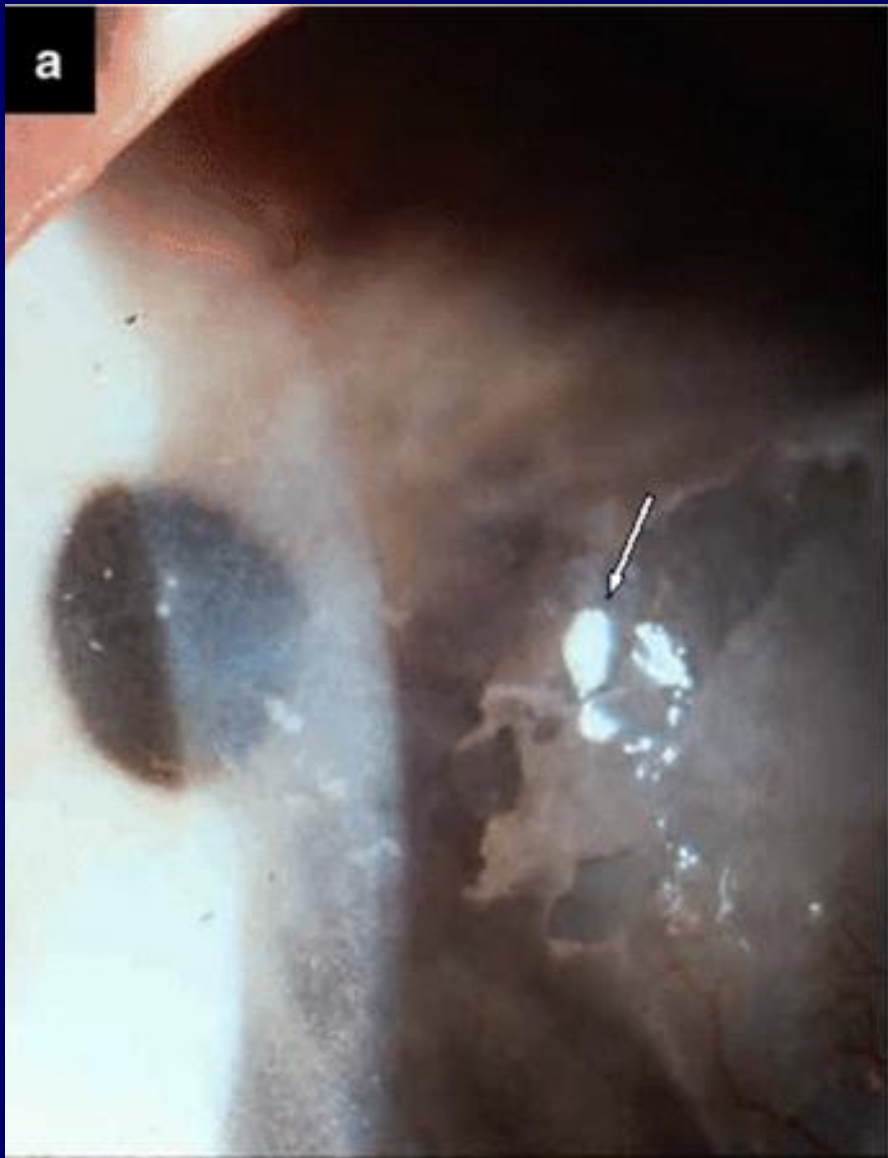


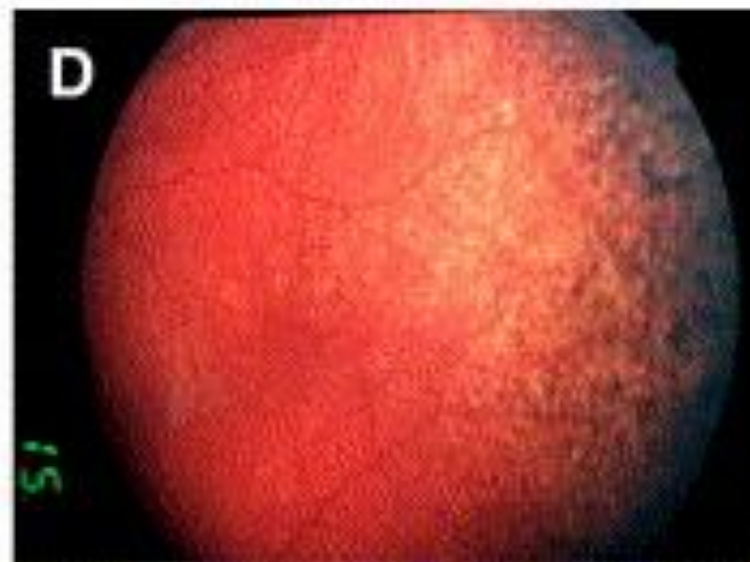
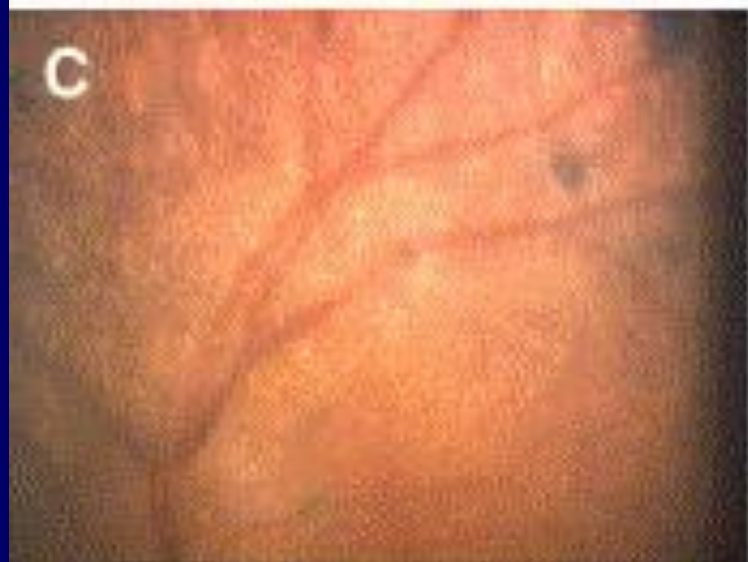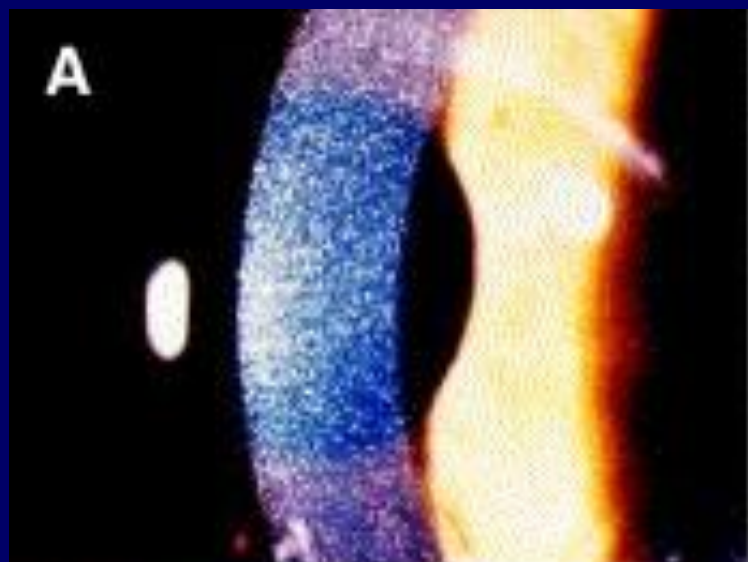Ocular Manifestations of Nephropathic Cystinosis

	Kaiser Kupfer 1986 8 pts	Richler 1991 18 pts
Renal transplant	8	8
Photophobia	8	13
Corneal deposition	8	18
Posterior synechiae	4	0
Crystals in lens	3	2
Poor colour vision	2	0
Retinopathy	0	17
Abnormal ERG	3/6	1/5

Kaiser Kupfer M.L. et al Arch Ophthalmol 1986 104 706 -711

Richler M. et al Arch Ophthalmol 1991 109 359 - 362





Randomized placebo-controlled trial of cysteamine eye drops

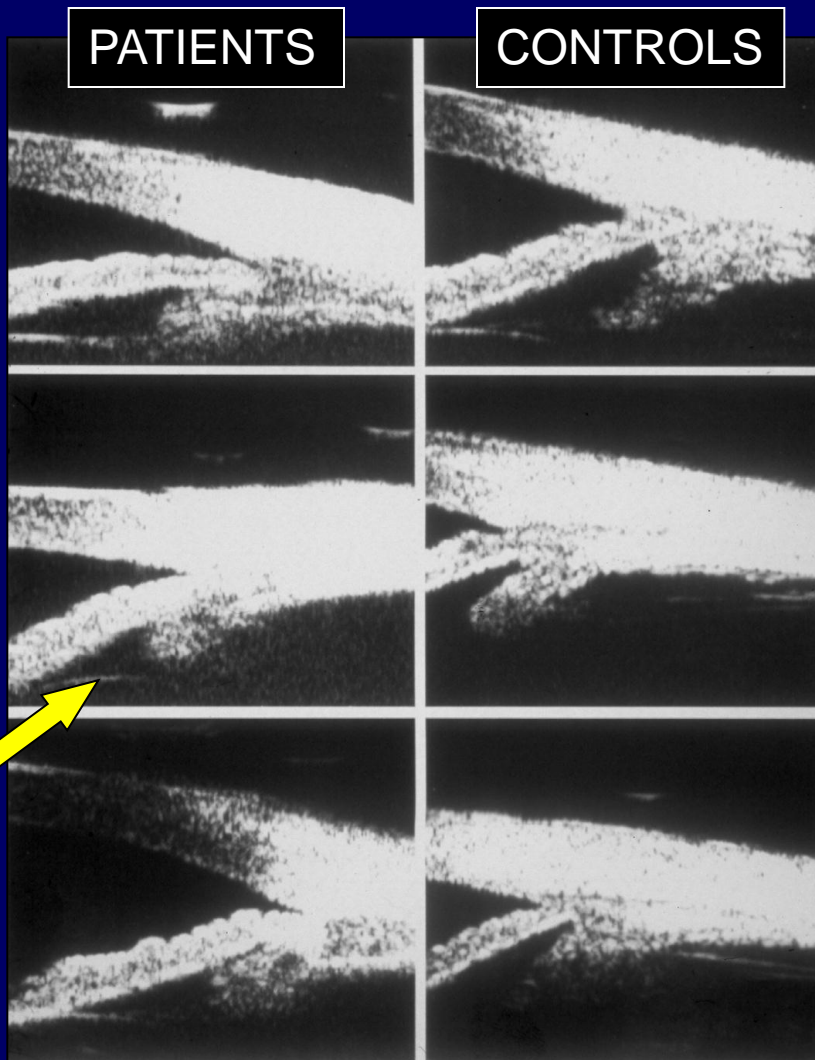
- 29 patients November 1985- September 1989
- One eye received drops, the other did not
- 15 patients no marked difference
- 4 patients unavailable for follow up
- 10 patients crystals 'cleared' in the eye taking drops
- 0.5% more effective than 0.1%
- Compliance was an issue
 - Kaiser Kupfer et al Arch Ophthalmol 1990 108 689 - 693

Ultrasound biomicroscopy of the eye in cystinosis

- 6 patients 16 – 25 years and 6 controls
- No patient had glaucoma or posterior synechiae
- All had crystals in trabecular meshwork
- Angle narrower in patients $p < 0.001$
- AC shallower in patients $p < 0.001$
- Findings similar to plateau iris syndrome
- Predisposition of patients to develop glaucoma

Mungan et al Arch Ophthalmol 2000

UBM Ultrasound in Cystinosis



This shows obliteration of the ciliary sulcus in patients resembling plateau-iris syndrome configuration

Thanks to
Mr K Ken Nischal
Study from Toronto

My clinic at St Thomas'

- Set up in 2008
- Every 3 months – over lunch time prior to appointments with Marlies
- 30% DNA - ? Eyes looked after elsewhere
- One patient blind (and has since died) due to a combination of severe corneal and retinal disease producing phthisis

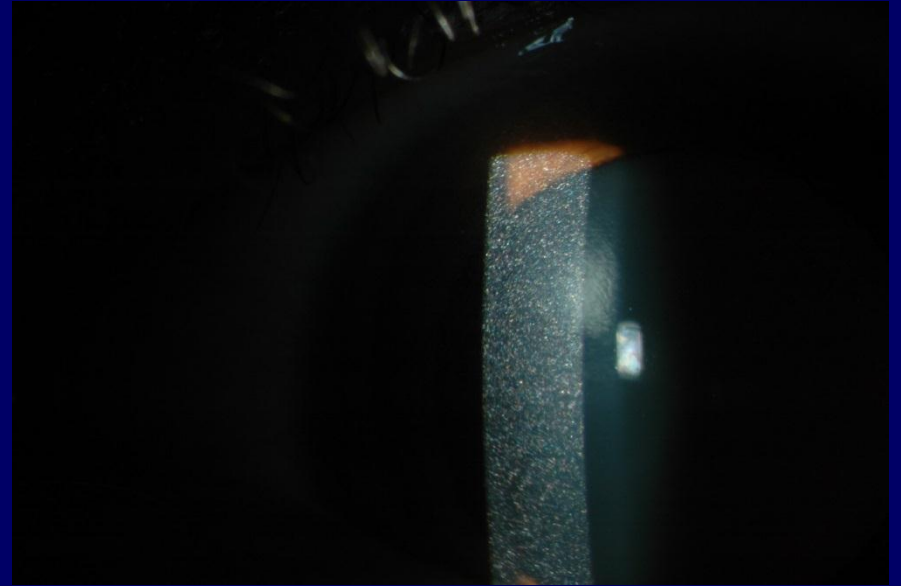
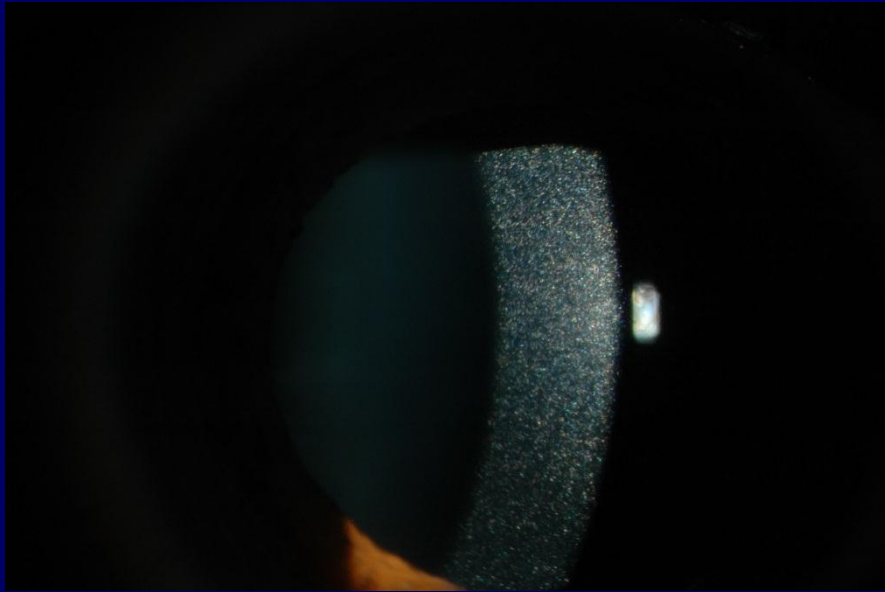
My patient cohort - demographics

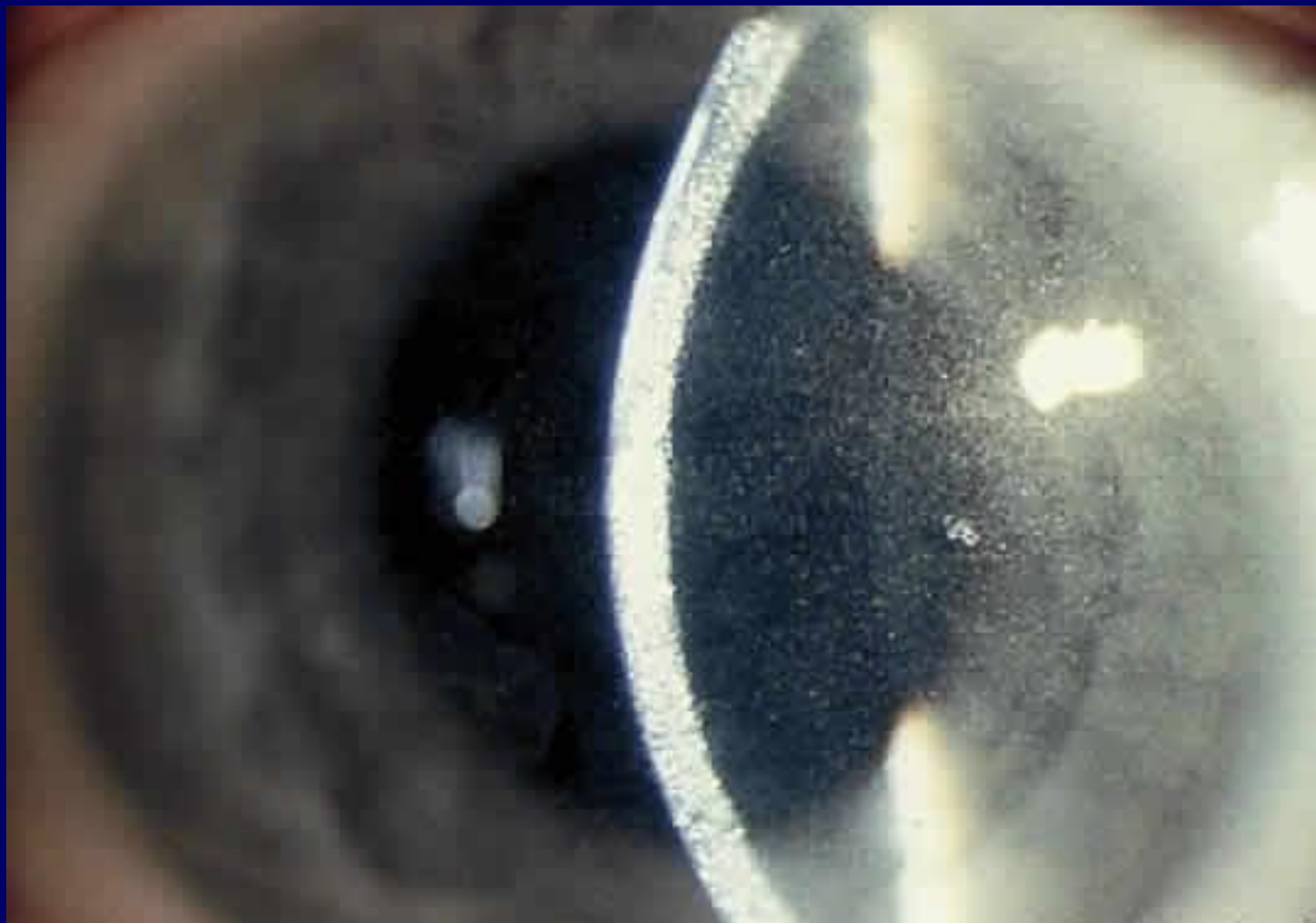
- 20 patients regularly attend; aged 16 – 45 years
- 9 patients do not take any drops - ? Why not
remainder take them between 1 and 8 x daily
- One patient developed acute angle closure glaucoma secondary to antidepressants
- All others have good vision and no particular visual problem e.g. night blindness, poor colour vision or constricted visual fields
- 4/20 wear contact lenses and tolerate them well
- 7/20 are photophobic

My patient cohort - signs

- No crystals whatsoever 1
 - Lots of crystals (cornea > conjunctiva > iris > retina) 19
 - Corneal degeneration 9
 - Retinal pigmentation 1
- NO correlation between
presence/absence drops and crystals
severity of corneal crystals and corneal change
- N.B. No retinal electrophysiology done

CYSTINOSIS





Cystinosis – treatment of eye disease

- 0.55% mercaptine (cysteamine) eye drops
- Trial soon of drops with more viscous base
- Penetrating keratoplasty in severe cases
- Excimer laser not indicated due to deposition of crystals throughout the cornea

Ocular manifestations of cystinosis in 2013

- Photophobic and may sneeze in bright light
- Needle shaped crystals in cornea
- Crystals elsewhere – conjunctiva > iris > retina
- May have predisposition to glaucoma but not in 2nd decade
- Retinal degeneration is rare
- The majority can drive
- Blindness most unlikely
- Proper prospective study would be interesting

